

A Classification and Algorithm for Treatment of Breast Ptosis

Laurence Kirwan, MD

Background: The Regnault classification of breast ptosis is insufficient for determining surgical strategies for different stages of ptosis.

Objective: A new clinical classification of breast ptosis is proposed that allows greater precision in the development of an appropriate surgical plan.

Methods: Breast ptosis is classified in 1-cm stages, beginning with stage A at 2 cm above the inframammary crease and continuing through stage E at 2 cm below the inframammary crease, with any level of ptosis beyond stage E defined as stage F. Increments of 1 cm were chosen because each level predicts a different amount of skin excision necessary to elevate the nipple-areolar complex to an ideal aesthetic level. An algorithm is provided for defining options for surgical management of the ptotic breast with and without augmentation and for the previously augmented breast.

Results: Seventy-three cases of breast ptosis were treated with augmentation mammoplasty, simultaneous areolar mastopexy breast augmentation, Wise mastopexy breast augmentation, and other procedures following the proposed classification system and treatment algorithm.

Conclusions: The new system for staging of breast ptosis is simple and easy to remember and can assist in the planning and evaluation of surgery. (Aesthetic Surg J 2002;22:355-363.)

From ancient times to the present day, the aesthetic female breast has been portrayed in art and photography as an organ symmetrical with the hips and supported by its own internal structure. Artistic representations of the ptotic breast in which the breast has lost volume and is supported by the chest wall are synonymous with aging, infirmity, and loss of attractiveness.

In the primary or nonaugmented breast, the ideal aesthetic nipple lies 7 cm above the inframammary crease (IMC), or at least 5 cm above the IMC if the nipple/IMC distance is short. A distance less than 5 cm above the IMC combined with a loss of the obtuse angle between the breast and the abdomen denotes some degree of ptosis. Since 1998, I have recommended that the ideal nipple/IMC distance in the augmented breast be 7 to 9 cm. Progressive descent of the breast results in the gland resting on the abdominal wall. The pencil test can be used to demonstrate ptosis. A positive test occurs when a pencil positioned at the IMC crease, with the patient in the standing position, is held in place by the weight of the breast resting on the lower rib cage.

In this article, the Regnault classification of ptosis is reviewed. A new system of staging of breast ptosis is described, and the stages defined in this system are linked to an algorithm for surgical treatment.

Dr. Kirwan is in private practice in Norwalk, CT, and London, England.

Material included in this article has been previously presented as an Instructional Course at the 67th, 68th, 69th, and 70th Annual Scientific Meetings of the American Society of Plastic Surgeons, 1998 to 2001; The Aesthetic Meeting 2001 and 2002 of The American Society for Aesthetic Plastic Surgery; and was published in the Proceedings of the Annual Breast Surgery and Body Contouring Symposium, cosponsored by The American Society for Aesthetic Plastic Surgery and the Plastic Surgery Educational Foundation, August 2001, Santa Fe, NM.

Accepted for publication March 22, 2002.

Reprint requests: Laurence Kirwan, MD, 605 West Avenue, Norwalk, CT, 06850.

Copyright © 2002 by The American Society for Aesthetic Plastic Surgery, Inc.

1090-820X/2002/\$35.00 + 0

70/1/126746

doi:10.1067/maj.2002.126746

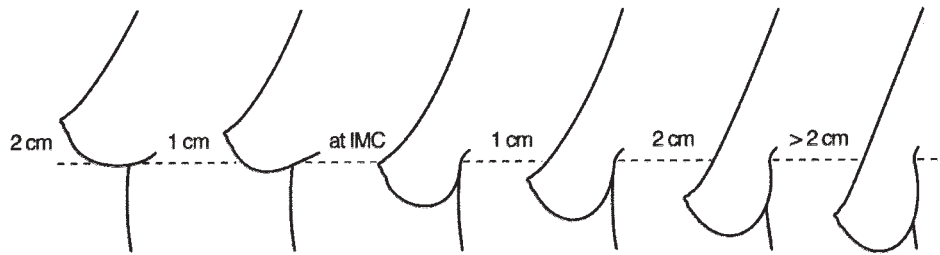


Figure 1. Classification of ptosis.

The Regnault Classification

In the Regnault classification,¹ the “pseudoptosis” designates a breast configuration in which the gland is inferior to the IMC and the nipple is above it. Grade I ptosis is diagnosed when the nipple is at or up to 1 cm below the crease. Grade II ptosis describes the nipple at a level 1 to 3 cm below the crease. Grade III ptosis describes a nipple more than 3 cm below the crease or at the inferior pole of the breast.

The inferior pole nipple-areolar complex (NAC) (grade III) is designated as an end point of ptosis, although the same anatomic configuration may occur in a tubular breast deformity with a high inframammary fold and lower pole parenchymal hypotrophy, as described by Brink.²

The Regnault system is based on 4 assumptions:

1. “True” ptosis occurs when the nipple drops to the level of the IMC
2. The term “pseudoptosis” applies to a ptotic breast when the nipple is above the IMC.
3. An inferior pole NAC requires a special designation.
4. An inferior pole NAC represents an end point of ptosis.

The Author’s Classification

The author has proposed a new system of staging for ptosis of the primary or nonaugmented breast.³⁻⁶ In this system, 6 stages of breast ptosis covering a 5-cm distance are defined (Figure 1). They are named alphabetically to avoid confusion with the Regnault system. Stages A to E progress in 1-cm increments as follows:

- Stage A: nipple position 2 cm above the IMC
- Stage B: nipple position 1 cm above the IMC
- Stage C: nipple position even with IMC
- Stage D: nipple position 1 cm below the IMC
- Stage E: nipple position 2 cm below the IMC.

In patients with either stage A or B ptosis, a positive pencil test advances the staging of ptosis by one stage.

The classification is based on 4 assumptions:

1. The normal nipple position in the nonaugmented breast is 5 to 7 cm above the IMC.
2. A nipple less than 2 cm above the IMC denotes some degree of ptosis when the angle between the breast and abdominal wall is less than 90 degrees.
3. The term “pseudoptosis” is irrelevant from the viewpoint of planning surgical treatment.
4. The concept of an inferior pole NAC is not necessarily an end point of ptosis.

The new classification begins with stage A (nipple 2 cm above the IMC). This is the level at which a breast augmentation may fail to give an adequate correction of a ptotic deformity. Above this level, the breast can be augmented without an additional mastopexy and with an optimal aesthetic result. Similarly, stage F (nipple greater than 2 cm below the IMC) is beyond the therapeutic limits of a periareolar mastopexy combined with an augmentation. These parameters are intended as guidelines only and are not dogmatic.

Stages B to E are set at 1-cm increments because each level defines a different amount of skin excision necessary to elevate the NAC to an aesthetic level, based on its initial and final relationship to the IMC. To evaluate the nipple level, a 12-inch ruler with a centimeter scale is placed at the IMC. The IMC level is marked at the midline with the ruler held in a horizontal position. With the same ruler, the nipple level is also marked at the midline. The difference in centimeters is measured.

The ptotic augmented, or secondary, breast is classified into 2 stages, depending on how much nipple elevation is required.⁷⁻⁹ In the secondary (previously augmented) breast, the nipple should be at or above the center of a circle delineated by the implant and the overlying breast. This is defined as a positive target sign. The nipple is situ-

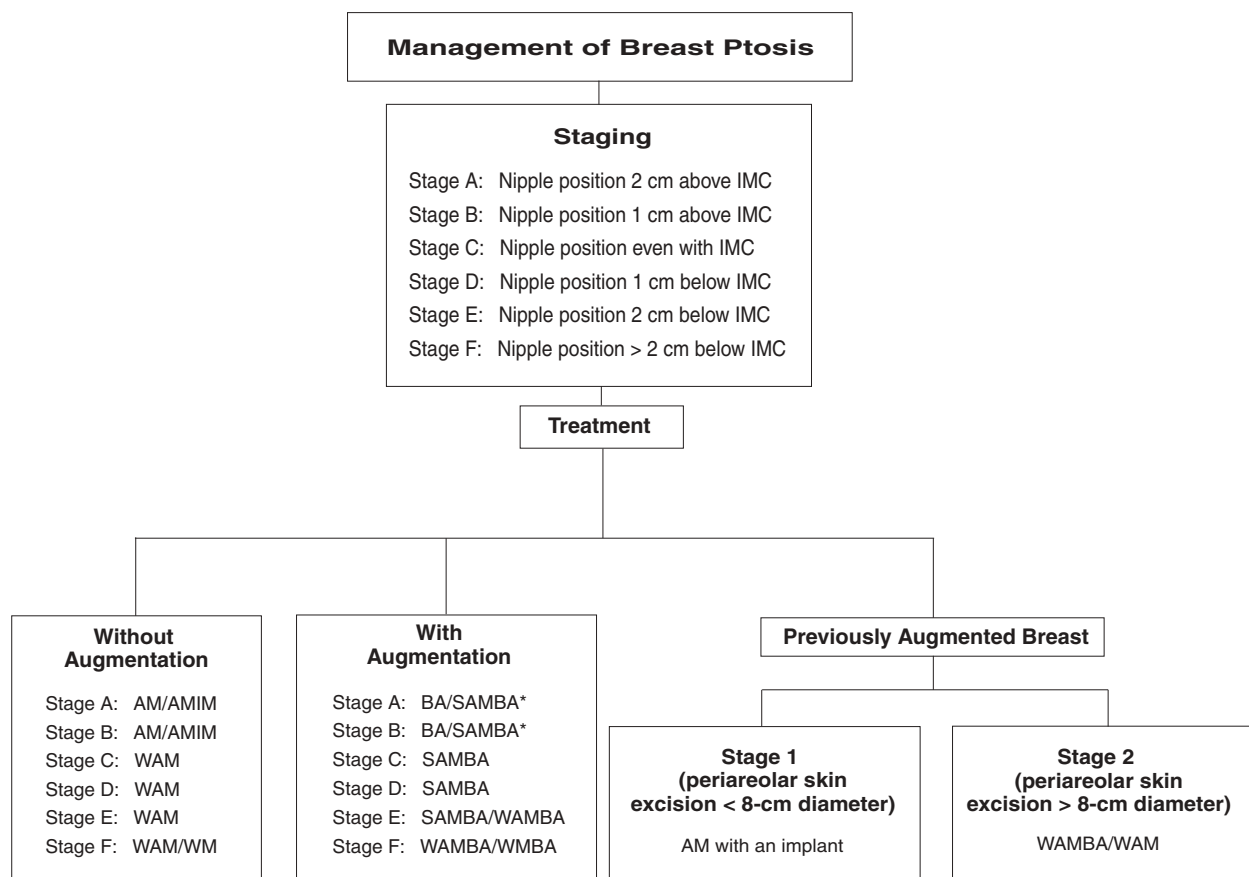


Figure 2. Algorithm for management of breast ptosis. AM, areolar mastopexy; BA, breast augmentation; IM, internal mastopexy; IMC, inframammary crease; SAMBA, simultaneous (peri)areolar mastopexy and breast augmentation; WAM, Wise pattern areolar mastopexy; WAMBA, Wise pattern mastopexy combined with an areolar mastopexy and breast augmentation with a short horizontal scar; WMBA, Wise pattern mastopexy and breast augmentation.

ated in the center of the circle, or “target,” outlined by the implant and overlying breast. Stage 1 is defined by a nipple that is 0 to 4 cm below the midpoint; stage 2 is defined by a nipple that is more than 4 cm below the midpoint.

An Algorithm for Surgical Treatment of Ptosis

I have previously presented the “SAMBA” technique¹⁰ and an algorithm for augmentation of the ptotic breast (Figure 2).³⁻⁷

Treatment of primary breast ptosis without augmentation

There are 3 options for management of the ptotic breast when electing not to perform an augmentation. An areolar mastopexy (AM) can be performed, either alone or combined with an internal mastopexy (AMIM). A mastopexy

incorporating a vertical scar can be performed, often combined with an areolar mastopexy to limit the length of any horizontal scar. This is described as a Wise pattern areolar mastopexy (WAM). The third option is a standard Wise pattern mastopexy (WM), usually combined with a superior pedicle and inferior wedge excision. The correct procedure may be determined during operation. The treatment options for each stage are as follow:

- Stage A: AM/AMIM
- Stage B: AM/AMIM
- Stage C: WAM
- Stage D: WAM
- Stage E: WAM
- Stage F: WAM/WM

Treatment of primary breast ptosis with an implant

The options for treatment of breast ptosis with an implant

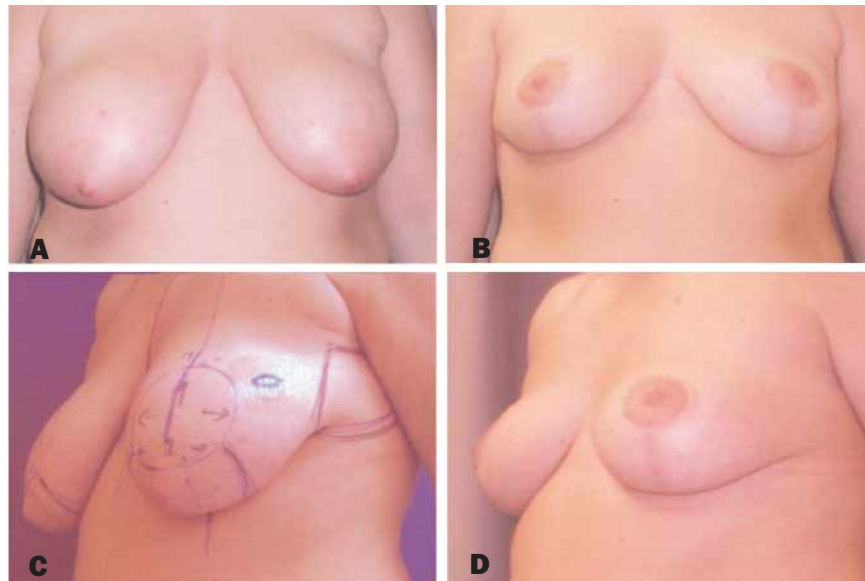


Figure 3. A, C, Preoperative views of a 32-year-old woman with stage E ptosis. B, D, Postoperative views 1 year after Wise pattern areolar mastopexy (combined areolar mastopexy and vertical mastopexy with a short horizontal scar).

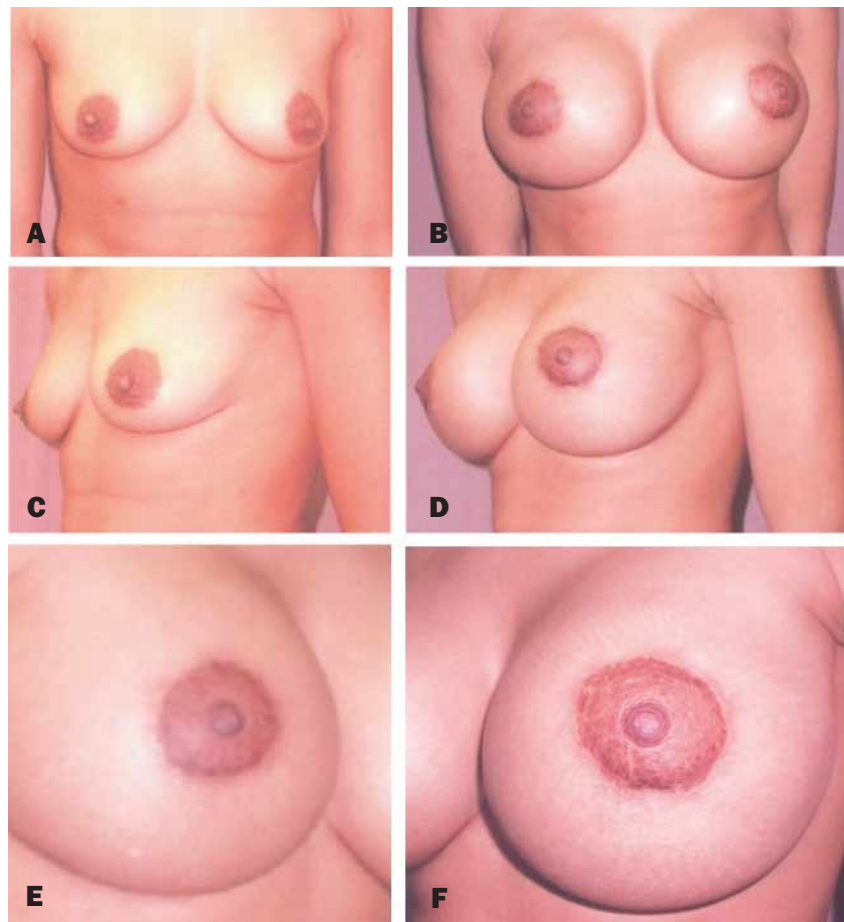


Figure 4. A, C, Preoperative views of a 31-year-old patient with stage A ptosis. B, D, Postoperative views 9 months after SAMBA with 550-cc gel-filled round smooth implants. E, F, Close-up views of scar.

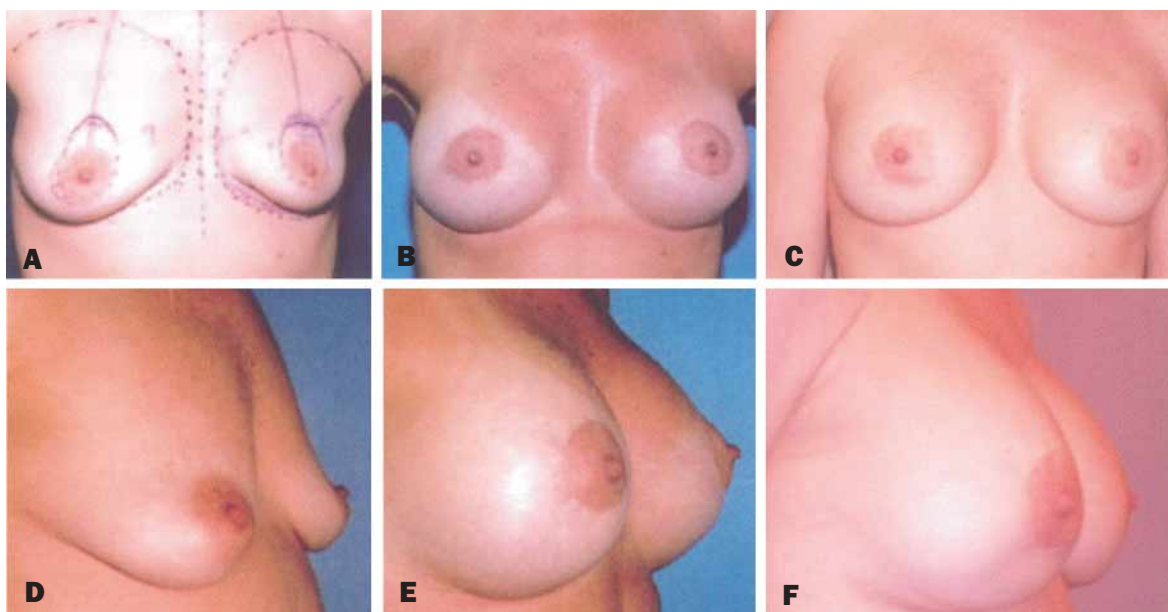


Figure 5. A, D, Preoperative views of a 42-year-old woman with stage B ptosis. B, E, Postoperative views 16 months after SAMBA with 360-cc gel-filled round textured implants. C, F, Postoperative views 6 years after SAMBA.

are breast augmentation alone (BA), Simultaneous (peri)areolar mastopexy and breast augmentation, (SAMBA), Wise pattern mastopexy combined with an areolar mastopexy, and breast augmentation with a short horizontal scar (WAMBA), or a standard Wise pattern mastopexy and breast augmentation (WMBA). The treatment options for each stage are as follows:

- Stage A: BA/SAMBA
- Stage B: BA/SAMBA
- Stage C: SAMBA
- Stage D: SAMBA
- Stage E: SAMBA/WAMBA
- Stage F: WAMBA/WMBA

In this algorithm, either breast augmentation alone or breast augmentation mastopexy may be appropriate for correction of stage A or B ptosis. SAMBA is generally appropriate when the nipple is 0 to 2 cm below the IMC and may also be appropriate when the nipple is 0 to 2 cm above the IMC. Areolar mastopexy is contraindicated for stage F ptosis with an implant. Areolar mastopexy may succeed with a breast augmentation but is usually compromised, leading to a less-than-ideal aesthetic result. A mastopexy alone would result in a vertical scar.

Treatment of the secondary (previously augmented) ptotic breast

As mentioned previously, the augmented ptotic breast is classified in 2 stages, depending on the amount of nipple elevation required. Stage 1 ptosis requires a periareolar skin excision of less than 8 cm diameter. The minimum treatment is AM.

Treatment of stage 2 ptosis requires a periareolar skin excision of more than 8-cm diameter. The recommended treatment is either a standard Wise pattern or modified Wise pattern mastopexy combined with an areolar mastopexy and short horizontal scar (WAMBA). If the implant is removed at either stage the maximum treatment is usually a WAM.

Results

A total of 73 breast ptosis cases were treated from June 1998 through May 2001 (Table). Among the 54 patients in this series who were treated with an augmentation mastopexy, 30 patients had a primary SAMBA procedure, 9 had SAMBA, 5 patients with implants in situ had a combined capsulectomy, mastopexy, and breast augmentation,

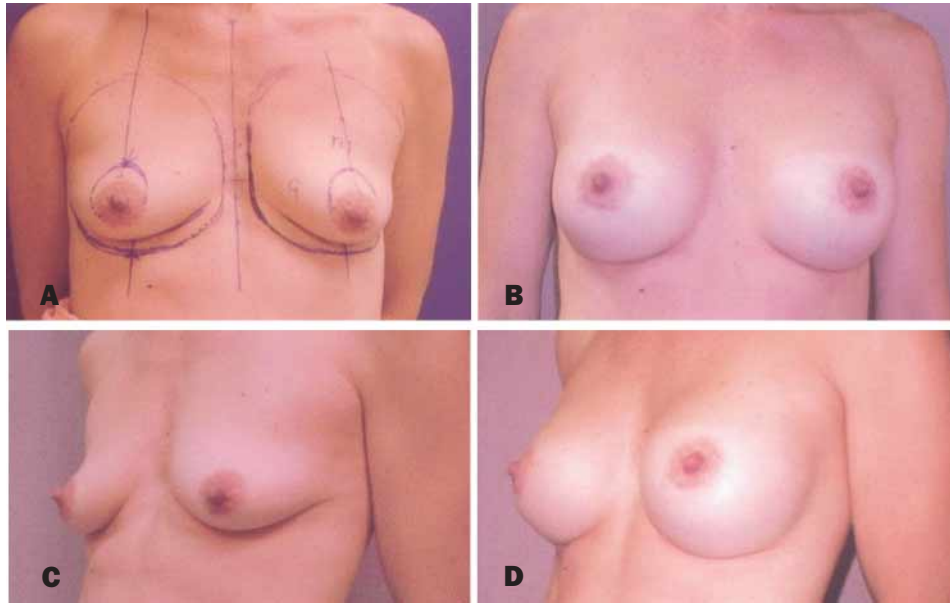


Figure 6. A, C, Preoperative views of a 36-year-old patient with stage C ptosis. B, D, Postoperative view 1 year after SAMBA with 360-cc gel-filled round textured implants.

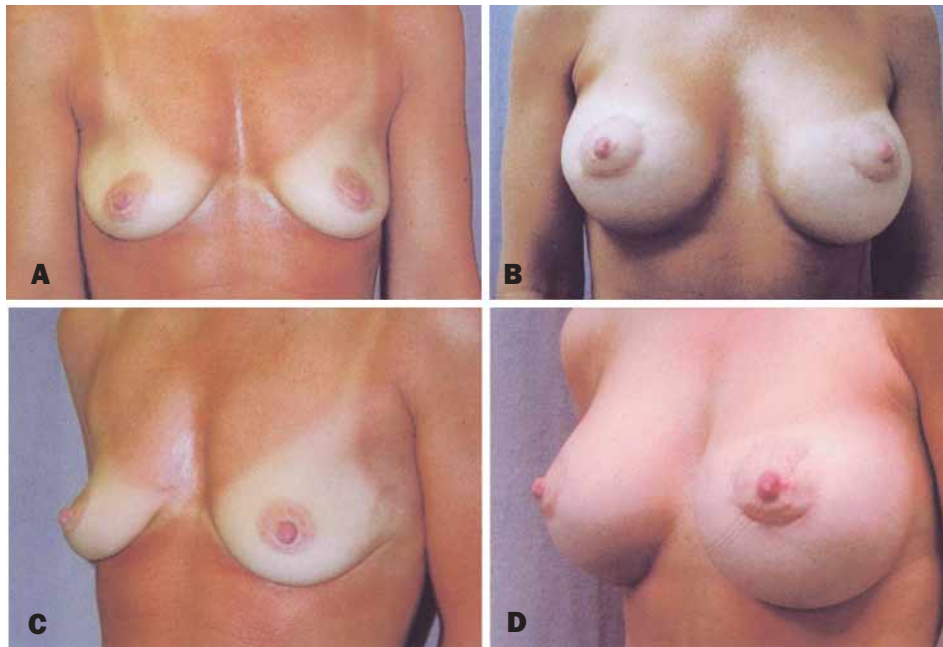


Figure 7. A, C, Preoperative views of a 36-year-old patient with stage C ptosis of the left breast and stage D ptosis of the right breast. B, D, Postoperative views 6 months after SAMBA with 360-cc saline-filled round textured implants.

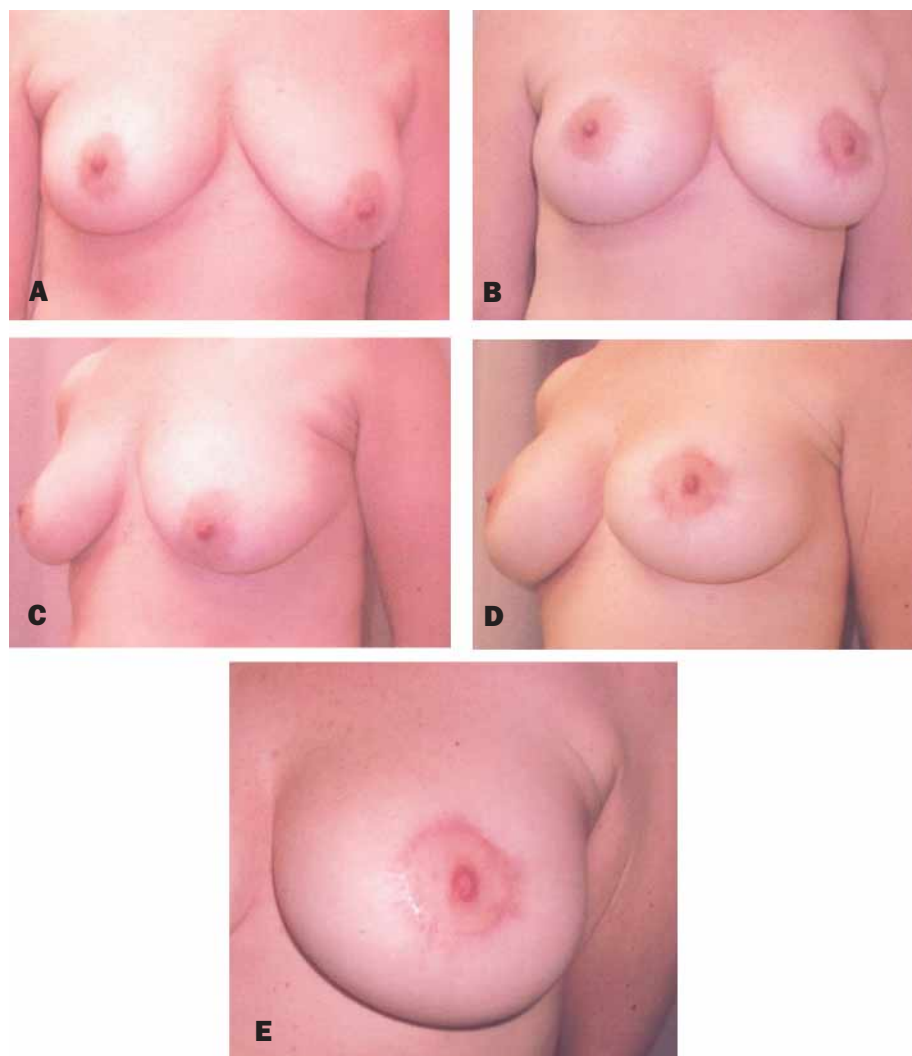


Figure 8. **A, C,** Preoperative views of a 49-year-old patient with stage C ptosis of the right breast and stage E ptosis of the left breast. **B, D,** Postoperative views 18 months after SAMBA with 300-cc saline solution-filled round smooth implants. **E,** Left periareolar scar revision 3 months after SAMBA.

and 10 patients had a WMBA. An additional 19 patients were treated with a mastopexy alone. During the same time period, 83 breast augmentations were performed without mastopexy. In all cases, the author's classification of breast ptosis and treatment algorithm was applied. Representative cases are illustrated (Figures 3 to 10).

Discussion

A new system of staging of breast ptosis is described that is simple and assists in planning and evaluation of surgery in a reproducible fashion. The advantage of this classification is that it indicates appropriate surgical strategies for

Table. Breast ptosis procedures performed

Procedure	No. of cases
Augmentation mastopexy	54
Primary SAMBA	30
Secondary SAMBA	9
Augmentation mastopexy + capsulectomy (implants in situ)	10
WMBA	5
Mastopexy only	19

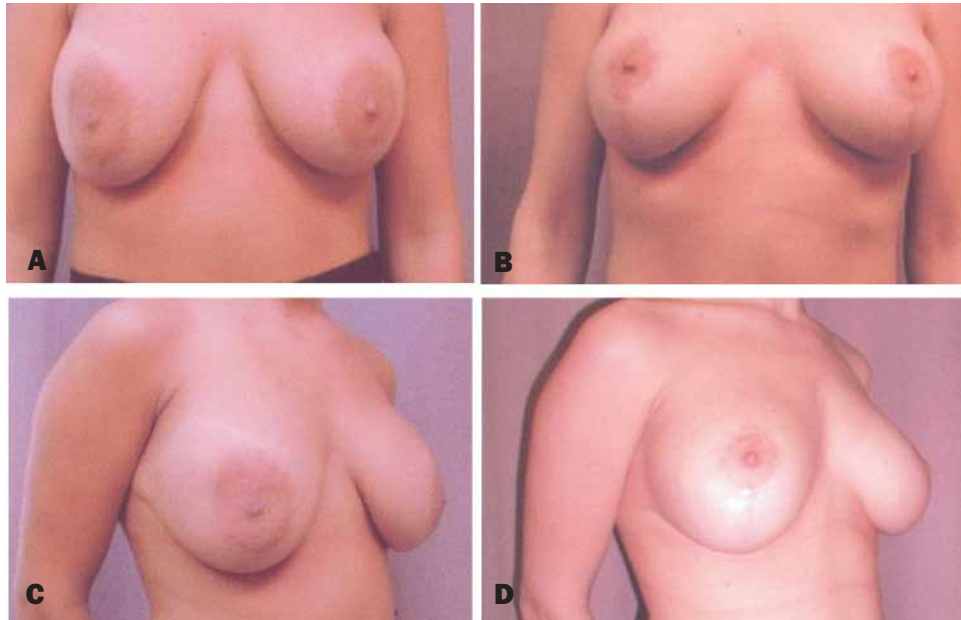


Figure 9. A, C, Preoperative views of a 29-year-old patient with stage 2 ptosis after prior augmentation. B, D, Postoperative views 11 months after WAMBA with 340-cc gel-filled round smooth implants.

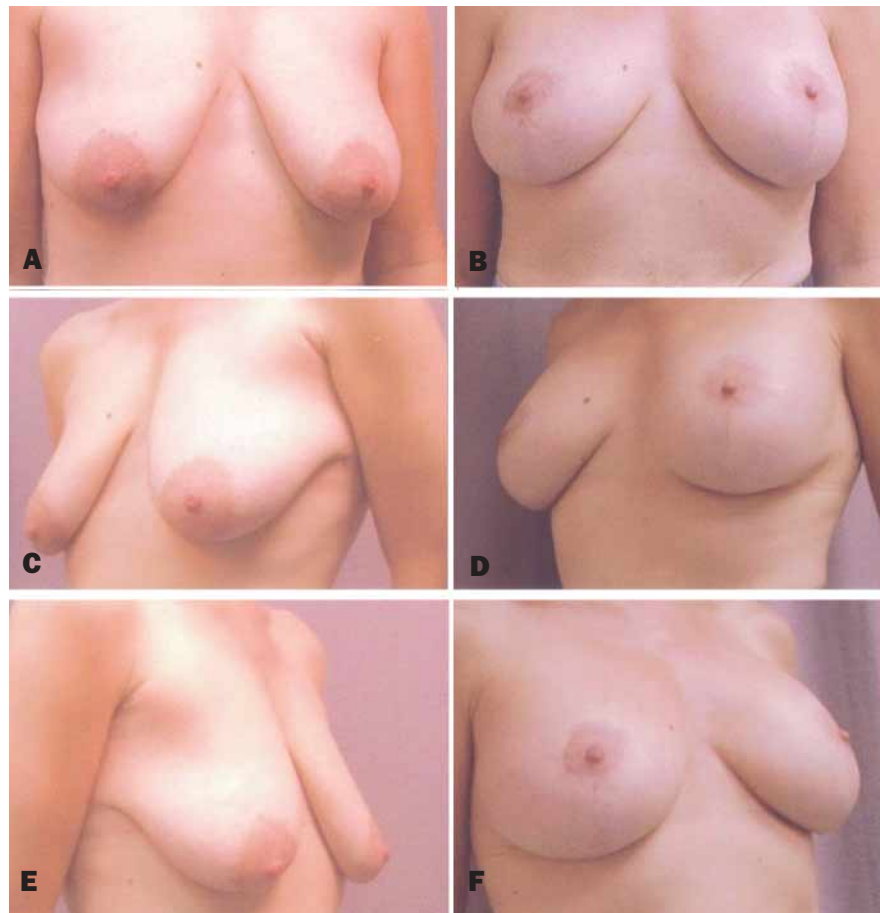


Figure 10. A, C, E, Preoperative views of a 41-year-old patient with stage F ptosis. B, D, F, Postoperative views after WAMBA with 300-cc gel-filled round smooth implants.

each specific stage of breast ptosis described. By contrast, the Regnault classification system is less useful for determining a surgical strategy. Regnault grade II includes degrees of breast ptosis consistent with treatment by use of a SAMBA procedure, as well as vertical scar mastopexy techniques. Grade III is no different, in terms of surgical treatment, from an end-point grade II.

The proposed classification system makes no attempt to isolate a breast shape on the basis of a definition of pseudoptosis or an inferior pole NAC, because these designations are irrelevant to the decision-making process and add another unnecessary layer of complexity and confusion to the clinical conundrum.

The high inframammary fold and lower pole parenchymal hypotrophy is relevant in the management of the ptotic breast but is not isolated from the general staging of ptosis. It is a marker of a tight IMC that may fail to release with insertion of an implant, even with parenchymal release as described.²

Conclusion

A new clinical classification of ptosis for primary and augmented breasts is presented that is a predictor of surgical

therapy. It is simple to remember and a useful tool for evaluating and measuring results. ■

References

1. Regnault, P. Breast ptosis: definition and treatment. *Clin Plast Surg* 1976;3:193-203.
2. Brink RR. Management of true ptosis of the breast. *Plast Reconstr Surg* 1993;91:657-662.
3. Kirwan L. Instructional course. 67th Annual Scientific Meeting of the American Society of Plastic Surgeons, Boston, MA, October 1998.
4. Kirwan L. Instructional course. 68th Annual Scientific Meeting of the American Society of Plastic Surgeons, New Orleans, LA, October 1999.
5. Kirwan L. Instructional course. 69th Annual Scientific Meeting of the American Society of Plastic Surgeons, Los Angeles, CA, October 2000.
6. Kirwan L. Instructional course. 70th Annual Scientific Meeting of the American Society of Plastic Surgeons, Orlando, FL, November 5, 2001.
7. Kirwan L. Instructional course. Aesthetic Meeting, 2000 of the American Society For Aesthetic Plastic Surgery, New York, NY, May 2001.
8. Kirwan L. Algorithm for augmentation of the ptotic breast. Proceedings of the Annual Breast Surgery and Body Contouring Symposium, Santa Fe, NM, August 23, 2001.
9. Kirwan L. Wise-pattern areolar mastopexy breast augmentation—the SAMBA procedure. Surgical strategies for the ptotic breast. Proceedings of the Annual Breast Surgery and Body Contouring Symposium, Santa Fe, NM, August 24, 2001.
10. Kirwan L. Augmentation of the ptotic breast: simultaneous periareolar mastopexy/breast augmentation. *Aesthetic Surg J* 1999;19:34-39.